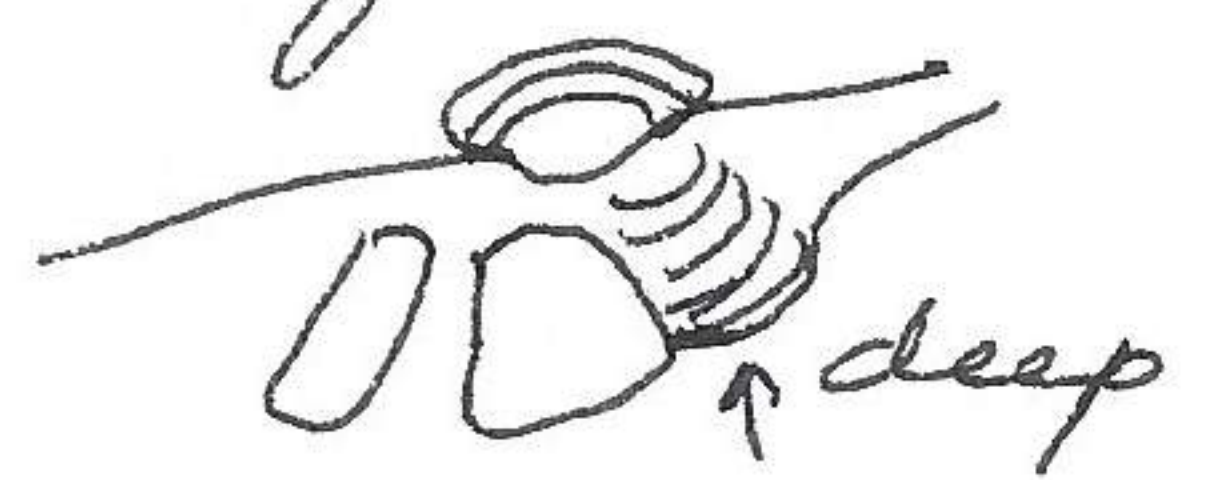


CRENODONTA PERUVIANA PERUVIANA

In comparison with *Megalonacis gigantea* which it closely resembles, *Crenodonta* is more rounded than *Megalonacis*. The valley of ^{right} pseudocardinal teeth, is deep in *Crenodonta* but shallow in *M. gigantea*.




The anterior scar in *Crenodonta* is more pointed and to anterior, whereas in *M. gigantea* it is rounded and apex is to center.



The hinge ligament is narrow in *Crenodonta* and wide in *M. gigantea*.

Hinge in *Megalonacis* relatively longer. Umbo cavity deeper in *Megalonacis*.



Megalonacis has (in some specimens not eroded on umbo) with characteristic wrinkles. Umbo of *Crenodonta* more anterior. Pallial line at posterior adductor muscle irregular ridges in *Crenodonta* anterior to lateral ridge but seldom beyond in *Megalonacis*.

